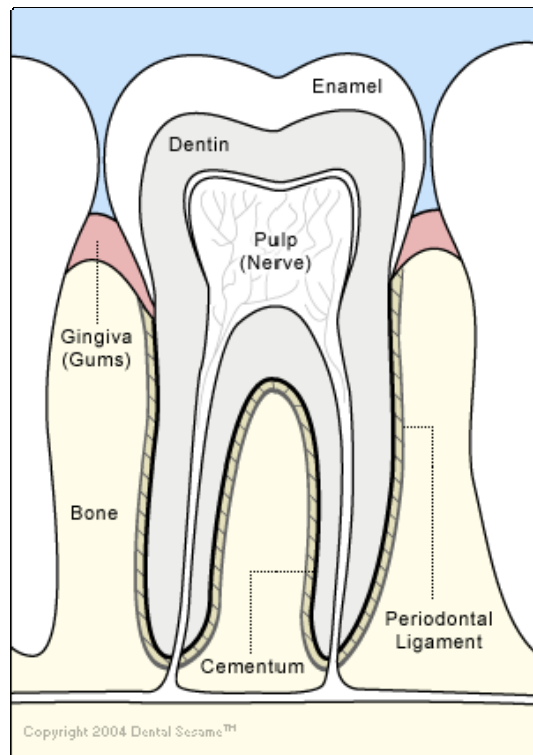


Anatomy of a Tooth



Cementum

A layer of tough, yellowish, bone-like tissue that covers the root of a tooth. It helps hold the tooth in the socket. The cementum contains the periodontal ligament that attaches the tooth to the bone.

Dentin

The hard but porous tissue located under both the enamel and cementum of the tooth. Dentin is harder than bone.

Enamel

The tough, shiny, white outer surface of the tooth that is visible. It holds the tooth in place. Enamel is the hardest substance in the body.

Pulp (Nerve)

The soft center of the tooth. The pulp contains blood vessels and nerves; it nourishes the dentin.

Gingiva (Gums)

The firm pink flesh inside the mouth. It covers the bones and surrounds the teeth.

Bone

The alveolar bone. It forms the tooth socket and provides the tooth with support.

Periodontal Ligament

The fleshy tissue between the tooth and the tooth socket. It holds the tooth in place.